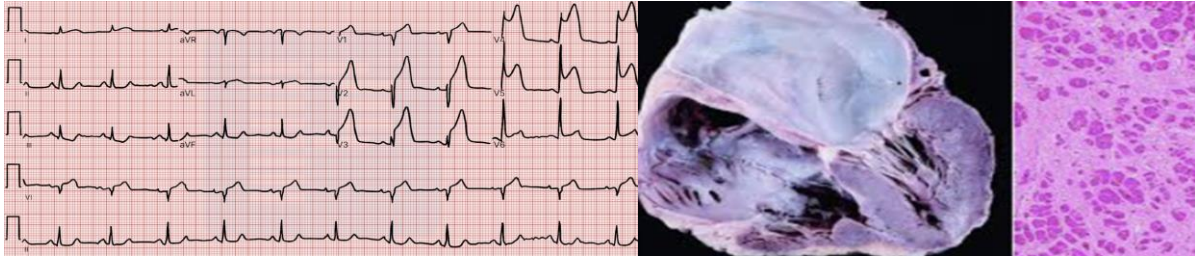


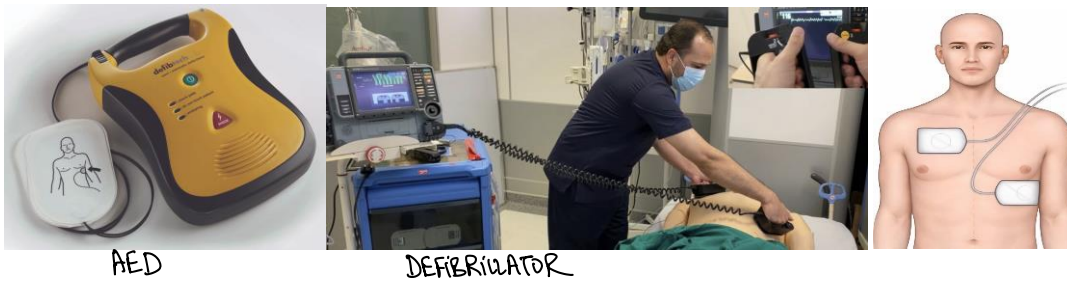**There are two days in the year
that we can not do anything,
yesterday and tomorrow.**

Cardiology



Topics color coded red are optional for FMG students

Crashing patient



AED

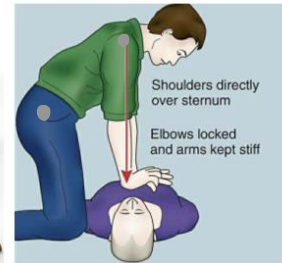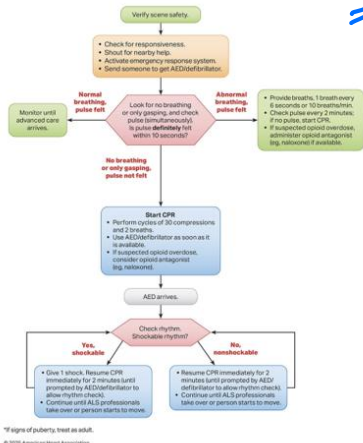
DEFIBRILLATOR

Q. You are posted in CCU and handling a 50 year old man admitted with diagnosis of Anterior wall STEMI. He becomes suddenly unconscious and resident identifies him as suffering from pVT. Which of the following is the first step to be done in management of this case?

- a. Check Carotid pulse for 6 seconds and asses breathing efforts
- b. Verify scene safety
- c. Immediately Place defibrillator leads and give DC shock
- d. Give chest compressions

PULSELESS V-Tachy

Q: You are at airport
Elderly Man, collapsed in front of you



ELECTRO CARDIOGRAPHY
V-FIBRILLATION

1. Check scene safety
2. Check responsiveness
3. Shout for help

call 911/102
AER 4. ACTIVATE EMERGENCY Response

AEDP 5. PROCURE Automated external defibrillator

10 sec ← 6. Look for No breathing, check Carotid pulsation

Chest compressions

Absent

1 breath / 6 sec

7. Start @ 30:2 Rescue breaths → 10/min
CPR

1 cycle CPR

2 min
Position swap
of Rescuers

Rate	100-120/min
Depth of sternal depression	5-6 cm
Site of chest compression	LOWER 1/3 STERNUM
Rationale	Maintain Cerebral blood flow
Fulcrum of movement	<ol style="list-style-type: none"> 1 Hip joint 2 Shoulder joint 3 Elbow joint 4 Wrist joint

MC Solid organ Traumatized during CPR
↳ LIVER (xiphisternum)

MC RIB # during CPR = 4-6th Rib





8. AED arrives → CONTINUE CPR : POWER ON device

Left pad placement	SICS, Lt, MAL
Right pad placement	2ICS, Rt, PSL

DC SHOCK 200 J biphasic

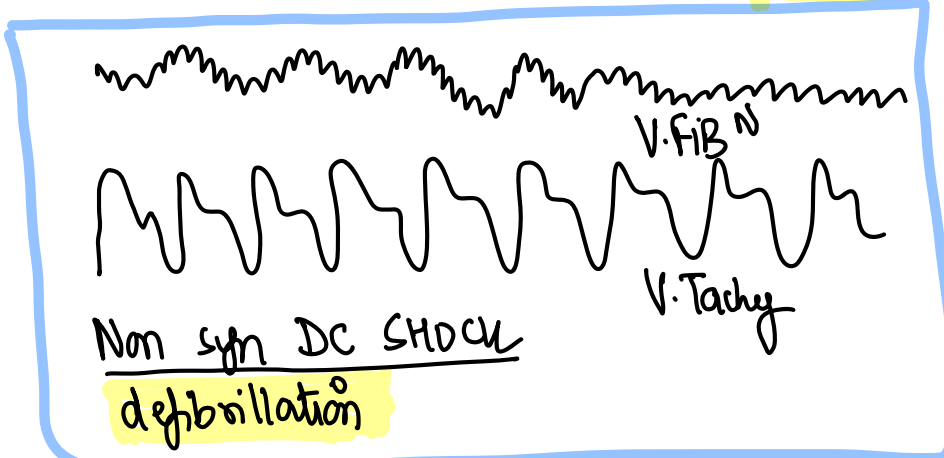

9. Check rhythm and if shockable give one shock and resume CPR, till AED gives next prompt for rhythm check . Continue till ALS team arrives

Extra mile

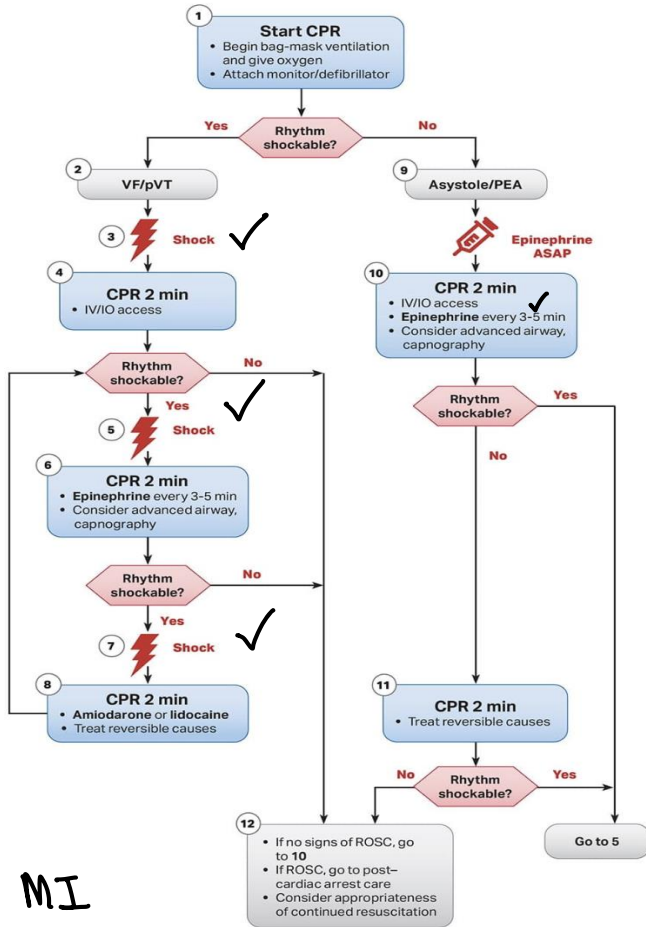
MC ribs fracture during CPR	4-6th RIB
MC solid organ traumatised during CPR	LIVER

Advanced life support

- ① iv ADRENALINE / EPINEPHRINE
- iv AMIODARONE or lignocaine
- iv ATROPINE



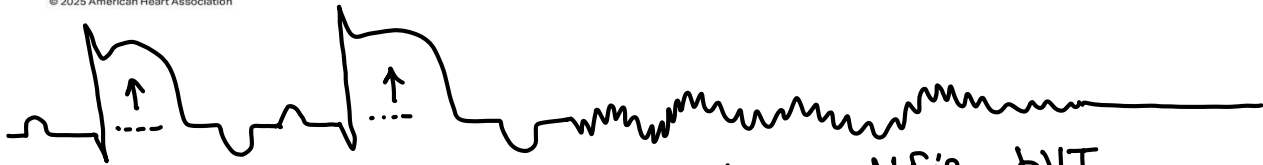
Adult Cardiac Arrest Algorithm (VF/pVT/Asystole/PEA)



- High-Quality CPR**
 - Push hard (at least 2 inches [5 cm]).
 - Push fast (100-120/min) and allow complete chest recoil.
 - Minimize interruptions in compressions.
 - Avoid excessive ventilation.
 - Change compressor every 2 minutes, or sooner if fatigued.
 - If no advanced airway, use 30:2 compression-ventilation ratio.
 - If advanced airway in place, give 1 breath every 6 seconds (10 breaths/min) with continuous chest compressions.
 - Continuous waveform capnography
 - If ETCO₂ is low or decreasing, reassess CPR quality.
- Shock Energy for Defibrillation**
 - **Biphasic:** Manufacturer recommendation (eg, initial dose of 120-200 J; if unknown, use maximum available. Second and subsequent doses should be equivalent, and higher doses may be considered.
 - **Monophasic:** 360 J
- Drug Therapy**
 - **Epinephrine IV/IO dose:** 1 mg every 3-5 minutes
 - **Amlodaron IV/IO dose:** First dose: 300 mg bolus Second dose: 150 mg or **Lidocaine IV/IO dose:** First dose: 1-1.5 mg/kg Second dose: 0.5-0.75 mg/kg
- Advanced Airway**
 - ET intubation or supraglottic advanced airway
 - Continuous waveform capnography or capnometry to confirm and monitor ET tube placement
- Reversible Causes**
 - Hypovolemia
 - Hypoxia
 - Hydrogen ion (acidosis)
 - Hypo-/hyperkalemia
 - Hypothermia
 - Tension pneumothorax
 - Tamponade, cardiac
 - Toxins
 - Thrombosis, pulmonary
 - Thrombosis, coronary

MI

© 2025 American Heart Association



* Sudden cardiac death in MI = ischemic V-FIB, pVT
 * MI: > 24 HOURS death ⇒ Cardiogenic SHOCK

✓ V-FIB^N : DC SHOCKS x 3
 pVT Non sync^N (defibrillation)

Rx for pVT and Ventricular fibrillation

Σ 1.

- CPR : 30:2 = 2min
- iv line / io access

Jamshidi needle
 Lateral To
 TIBIAL TUBEROSITY

Σ (2)

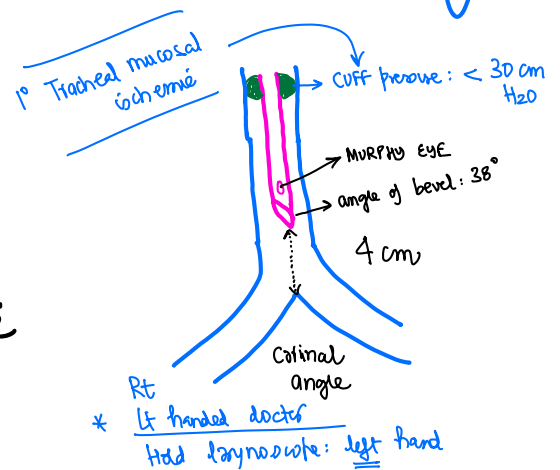
1mg / 1ml : 1 : 1000 dilution
 10cc syringe : 1ml NS

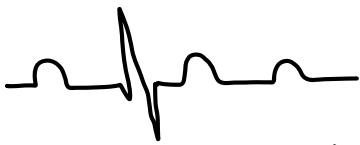- CPR : 30:2 : 2min
- iv / io Epinephrine : 1mg : 10,000

* - E-Tube / advanced airway : Capnography
 ET CO₂ : 35 mm Hg

Σ (3)

- CPR : 30:2 : 2min
- iv Amiodarone / lignocaine
- Treat the cause





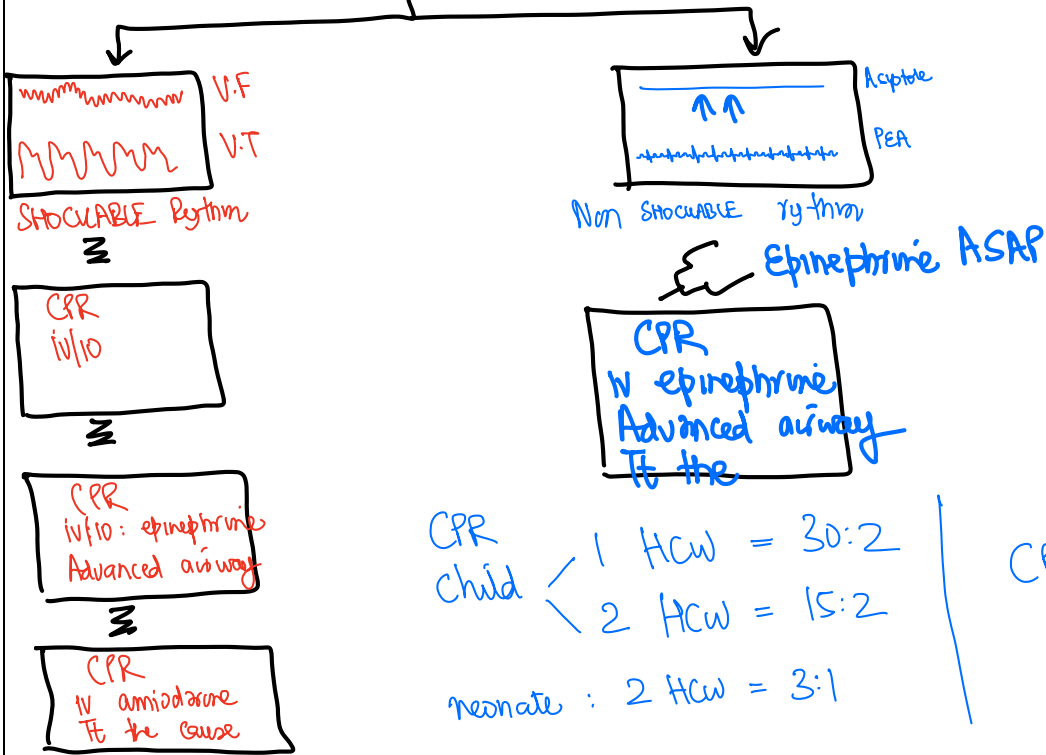
cardiac ARREST

Asystole management

1. CPR @ 30:2
 2. $\frac{IV}{10}$ Epinephrine 1mg:10,000
Repeat @ 3-5 min interval
- ↓
 CONVERT asystole → V.FIB^N

ALS: CRASHING pt

1. CPR: 30:2
2. B & M: 10/min breaths
3. attach defibrillator pads

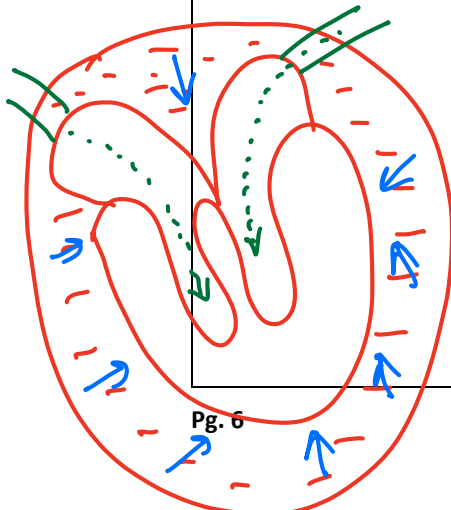


Cardiac Tamponade

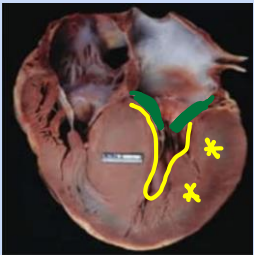
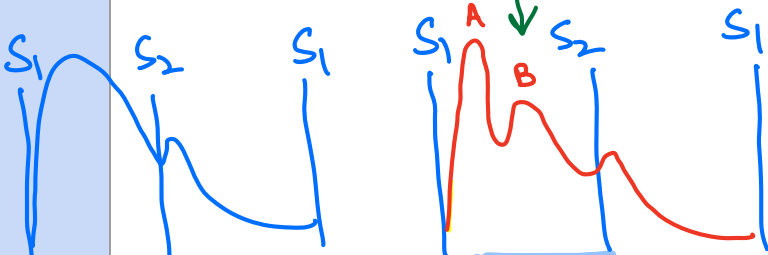
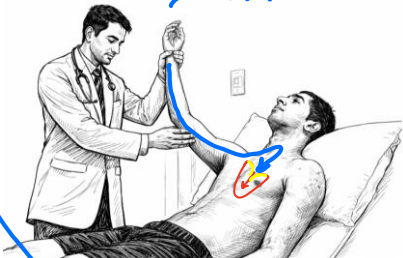

- EDV ↓↓
- SV ↓↓
- CO ↓↓
- BP ↓↓
- pulse ⊖

heart is beating!

- * P.E.A
- * Non shockable rhythm
- * OBSTRUCTIVE SHOCK



ABCD of Pulse

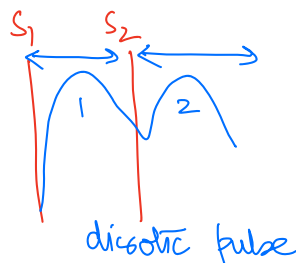
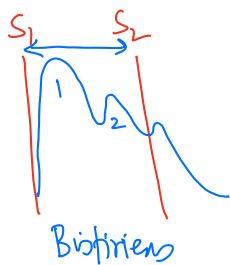
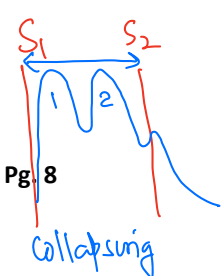
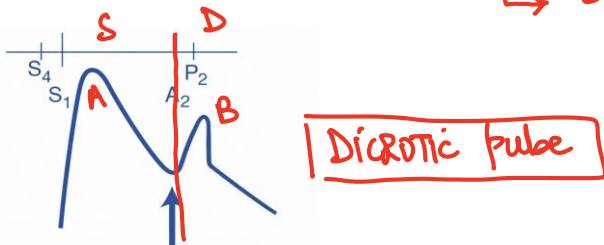
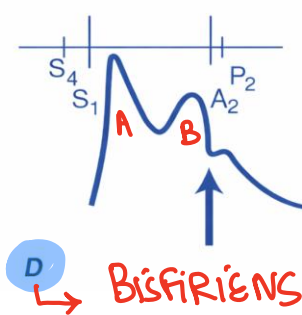
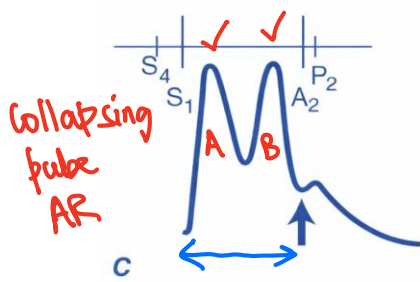
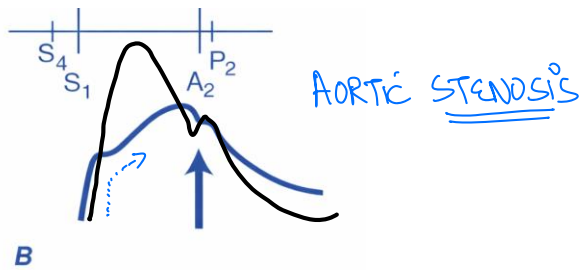
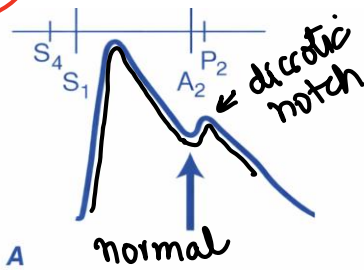
<p><u>Al</u>ternans</p> <p><u>An</u>acrotic (Pulsus Parvus et Tardus)</p>	<p>LVF : </p> <p>AORTIC STENOSIS ↓ Slow Rising</p>
<p>Bisferiens, JERKY pulse → Twice beating pulse in systole</p>  <p>HCM</p>	 <p>→ SUB-Valvular AORTIC STENOSIS</p>
<p>Collapsing pulse with pistol shot sounds → FEMORAL A</p>  <p>WATER HAMMER pulse</p>	<p>AORTIC REGURGITATION</p> <ul style="list-style-type: none"> * dancing carotids * PISTOL SHOTS * <u>ANKYLOSING spondylitis</u> <p>MARFAN syndrome</p>
<p>Dicrotic pulse</p> <p>↓ dilated cardiomyopathy ↑ ALCOHOL</p>	 <p>Twice beating pulse: S + D</p>

* SLE: Libman Sacks endocarditis
: MR
* MARFAN: death: Aortic dissection.

<p>Pulsus paradoxus</p> <p>↓</p> <p>SBP falls > 12 mm Hg on deep inspiration</p>	<p>Mnemonic: MR-CAP</p> <p>Massive PE</p> <p>RV MI <i>my wall Mi</i></p> <p>Cardiac tamponade</p> <p>Asthma (status asthmaticus)</p> <p>Pericarditis Constrictive</p>
<p>Irregularly irregular pulse</p>	<p>1. A-Fib^N</p> <p>2. M.A.T</p>

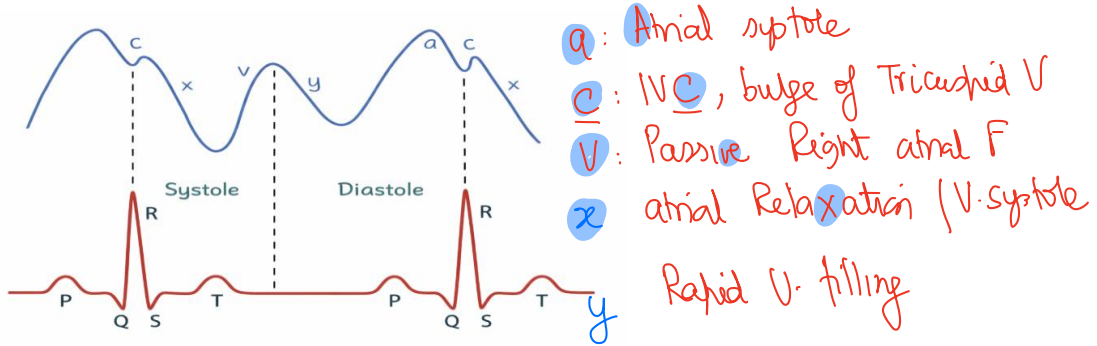
Line diagrams for types of pulses

ANACROTIC pulse



Abnormalities of JVP

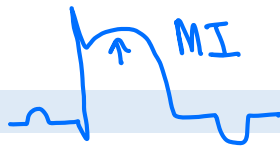
Normal JVP value: 5-8 cm H₂O is evaluated in internal jugular vein



✓ **Kussmaul sign:** Paradoxical rise of JVP on deep inspiration
CONstrictive Pericarditis, Restrictive cardiomyopathy
Mnemonic: **Cops restrict right heart** Right sided HF

Large a waves *	<p>TRICUSPID STENOSIS PULMONIC STENOSIS PAH mean > 20 mm Hg</p>
Absent a waves	Atrial Fibrillation
Cannon a waves Frog sign	AV dissociation HR ↓ : - Complete H. Block HR ↑ : - V-T, PSVT
Absent x descent	<p>TRICUSPID REGURGITATION</p> <p>steep y descent cv wave</p>
Absent y descent	<p>CARDIAC TAMPONADE</p>
* Steep x and absent y descent	CARDIAC Tamponade
✓ Steep x and steep y descent	<p>CONstrictive PERicarditis</p>

Pericardial diseases




	<p>Acute pericarditis</p> <p>VIRAL, TB, RHD, malignancy, URAEMIA →</p>	<p>Pericardial effusion</p> <p>① Fwid = 20-50ml</p>
ECG	<p>ST ↑ Concave upwards</p> <p>PR segment depression: most specific</p>	<p>* low voltage ECG or R+S < 5mm: LL</p> <p>* ELECTRICAL ALTERNANS</p>
CXR	<p>NORMAL CT RATIO</p> <p>↓</p> <p>≤ 0.5</p>	<p>WATER BOTTLE ♥</p> <p>Money Bag app</p>
Rx	<p>Dressler syndrome</p> <p>AUTOIMMUNE</p> <p>MI → Chest pain at Rest</p> <p>6 wks ECG: ST ↑ concave upwards</p> <p>Troponin I: NORMAL</p> <p>Rx: ASPIRIN ♀</p>	<p>TB</p> <p>Oat cell Cancer =</p> <p>Echo guided pericardiocentesis</p> <p>↓</p> <p>* CBNAAT</p> <p>* CYTOLOGY, IHC</p>

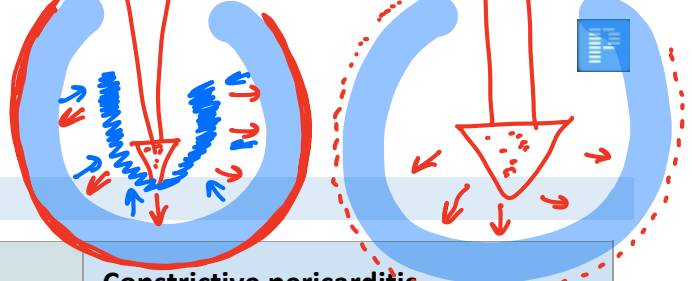
STEROIDS
😊

Rx: TB pericardial effusion = A.T.T x 12 months

Oat cell Ce lung = CISPLATIN + IRINOTECAN



Cardiac tamponade vs Constrictive pericarditis



	Tamponade	Constrictive pericarditis ATT: ✓ PERICARDIAL shudder
→	MUFFLED S ₁ S ₂	
Pulse	— PULSUS PARADOXUS —	
JVP character	JVP ↑ non pulsatile	Kussmaul sign JVP ↑
JVP waves	Steep x & ⊖ y descent	Steep x Steep y
BP	↓↓	Ⓝ / ↓
ECG	Low voltage ECG: fluid	Low voltage ECG ↳ Calcification
CXR	Money bag ♡ H ₂ O bottle ♡	CT Ratio Ⓝ Calcification +/-
Rx	Pericardiocentesis	PERICARDIAL : CTVS STRIPPING

low voltage ECG = Pericardial effusion

low voltage ECG = cardiac Tamponade

+ BP ↓↓ : < 90/60

- low voltage ECG
- 1. MYXEDEMA } fluid
 - 2. PERICARDIAL EFFUSION } fluid
 - 3. CARDIAC TAMPOUNADE } fluid
 - 4. CONSTRICTIVE PERICARDITIS } calcification

Acute pericarditis → P. effusion → cardiac Tamponade

PERICARDIAL friction Rub
Pg. 11

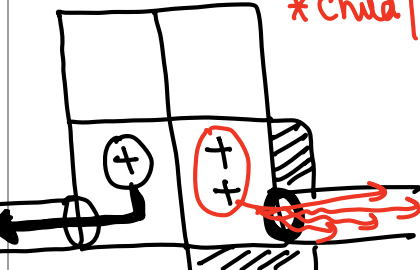
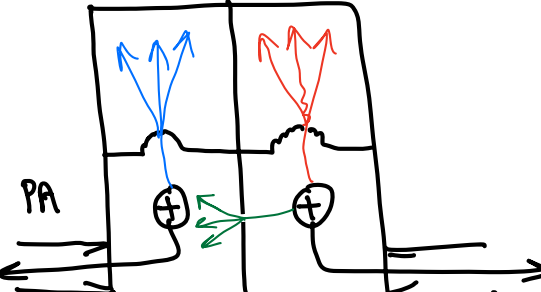
m

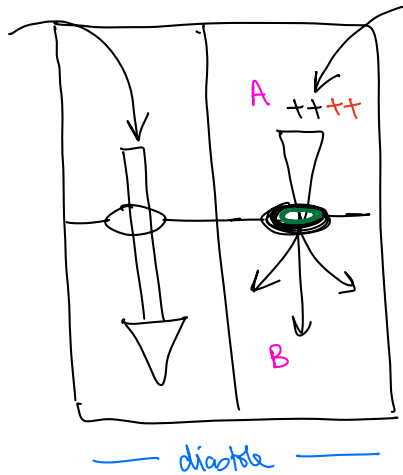
MUFFLED S₁ S₂

low diastolic sound

C.P
PERICARDIAL SHUDDER,
KNOCK, SHOCK

Murmurs

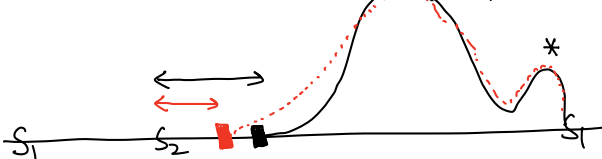
Ejection systolic murmurs	Pansystolic murmurs
<p>Mnemonic: PASS PULMONIC STENOSIS: <i>NOON AN SYN</i> AORTIC STENOSIS</p> <p><i>* child / > 65yr</i></p> <p>S: syncope A: angina D: dyspnea</p> <p>↓ <i>S₁ S₂</i></p> <p>MC valve lesion: <i>import: AS</i> <i>" " " RHD: Sys: MR</i> <i>> : 18yr: MS</i></p> 	<p>Mnemonic: MTR-Vada MITRAL REGURGITATION TRICUSPID VSD</p> 



SEVERITY of MS

X INTENSITY MURMUR X loud P₂
X loud S₁ ✓ length of MURMUR

SEVERITY of MS \propto $\frac{1}{S_2 - \text{opening snap}}$



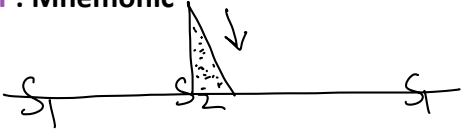
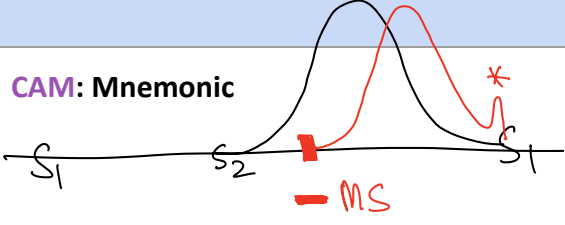
- * loud opening snap
- * - MID-DIASTOLIC MURMUR -
- * \bar{c} PRE-SYSTOLIC ACCENTUATION
- * PSA: \ominus : A-FIBRILLATION

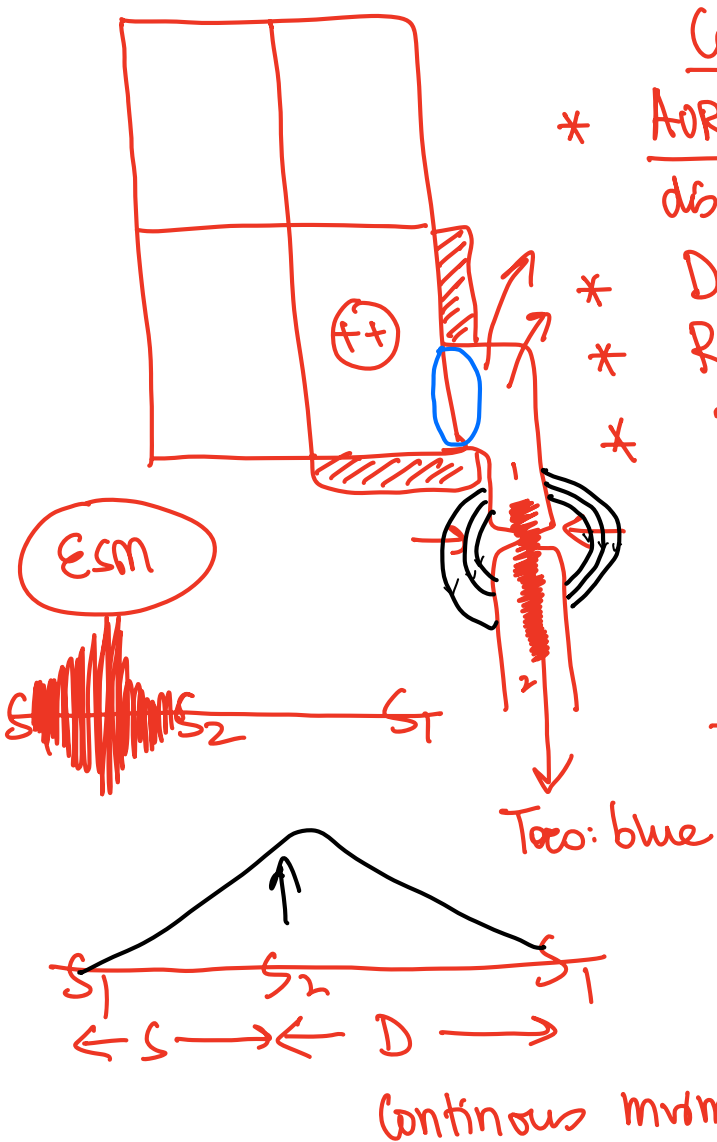
LOC: Echo

Rx: P.M.B.V : SEVERE MS

Prosthetic ← SEVERE calcified MS

- Value
- metallic V : life long (durable), warps in
- Bioprosthetic : SHORTER life span, no need of warps in
- ↳ BOVINE, PORCINE : XENO GRAFT
- ↳ CADAVERIC : HOMOGRAFT

Early diastolic murmur	Mid diastolic murmur
<p>GAP: Mnemonic</p>  <p>1. GRAHAM STEELE MURMUR * SEVERE PAH, MILD PR</p> <p>2. AR mid</p> <p>3. PR mid</p>	<p>CAM: Mnemonic</p>  <p>1. CAREY CROMBIE in characteristic murmur of ARF, valvulitis</p> <p>2. Austin-flint murmur SEVERE AR</p> <p>3. MS</p>



CoA

* AORTIC Isthmus : MC sites
distal to origin of left subclavian A

* DIFF CYANOSIS

* RADIO FEMORAL delay

* BP normal

UL < 120/80

LL < 140/80

BP : **CoA**

UL : **INCREASE**

LL : **Reduced**

loc: MRA

Toe: Balloon dilatation

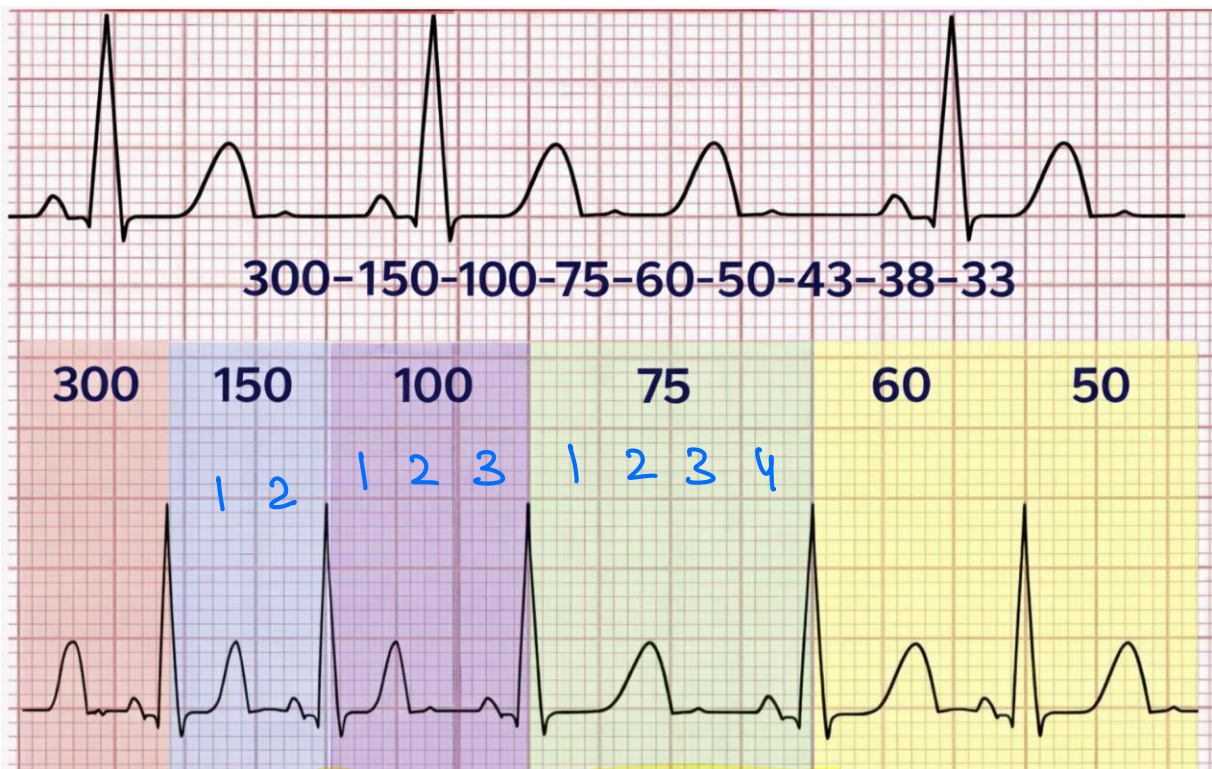
Continuous murmur

Connaught place main Hum-Tum!

1. Coarctation of Aorta
2. PDA
3. Mammery soufflé : \uparrow I.M.A Flow
4. Venous hum dilated veins
5. Peripheral pulmonic stenosis

lead II, HR = $300 / \text{R-R interval}$: large squares

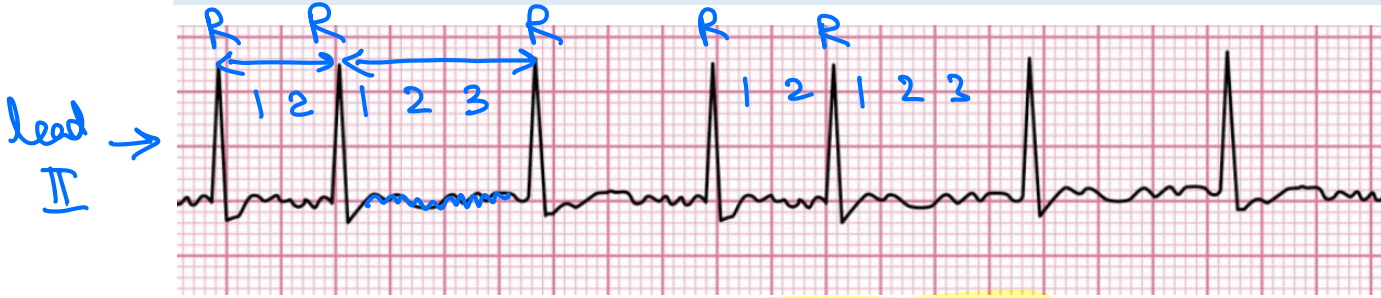
How to calculate heart rate under 5 seconds



$< 3 \text{LS} : \text{R-R} : > 100 / \text{min}$

Tachy and Brady Arrhythmias

Atrial fibrillation



ECG criteria

IRREGULAR R-R interval
P wave ⊖

Why?: HTN, Ischemic cardiomyopathy, alcohol, grave's DCM

Rate control : ESMOLOL iv

Rate control in patients with coexistent poorly controlled asthma * iv VERAPAMIL

Rate control in patients with coexistent COPD * iv VERAPAMIL

Rate control in patients with acute pulmonary edema * DIGOXIN
BL CREPTS ⊕, BNP: ↑

Recent onset atrial fibrillation with crashing BP : CARDIOVERSION
→ Clots in L.A. appendage

How to manage long standing atrial fibrillation * R-A-C-E

How to decide on Anticoagulation?

CHF, HTN, age > 75yrs (2) Echo: T.E.E
DM, STROKE HISTORY (2), CHADS₂-VASC
Vascular disease, age: 65-75yrs
Sex Category: ♀

Drugs used for anticoagulation in Atrial fibrillation

≥ 2 : NVAf (VODKA/BEER) = oral Apixaban
VAF: RHD + MS = oral warfarin/VKA

Rhythm control

Chemical cardioversion

— oral amiodarone

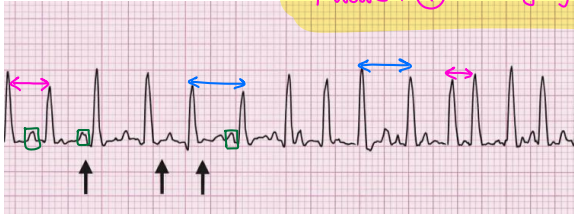
M/C : Corneal microdeposits

- ✓ most life threatening S/E: pulm. fibrosis
- ✓ T₄ ↓, T₄ ↑

Multifocal atrial tachycardia vs Atrial flutter

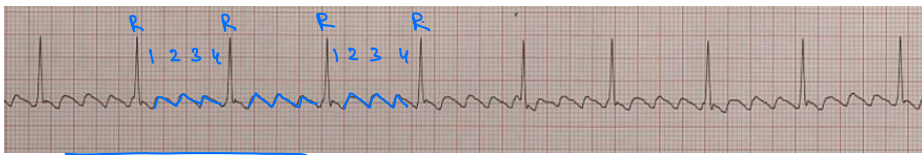ECG findings of MAT

IRREGULAR - R-R interval
P wave: ⊕ varying morpho



copd clo palpitations
Rx ⇒ iv verapamil

ECG findings of Atrial flutter



SAW TOOTH WAVES

EEG = REM
barium enema = diverticulosis


@ 11/min

Rx for Atrial flutter	RX for MAT
<p>RACE</p> <p>Rate control: <u>β Blocker</u> CCB</p> <p>anticoagulation: apixaban</p> <p>Chemical cardioversion: amiodarone</p> <p>Rhythm control</p> <p>electrical cardioversion</p>	<p>DC SHOCK: Limited success</p> <p>* Rx the cause: <u>COPD</u></p> <p>Target spo₂: 88-92%</p> <ol style="list-style-type: none"> 1. L.T.O.T : Long TERM 2. LABA ⇒ INDACATEROL 3. LAMA 4. ICS

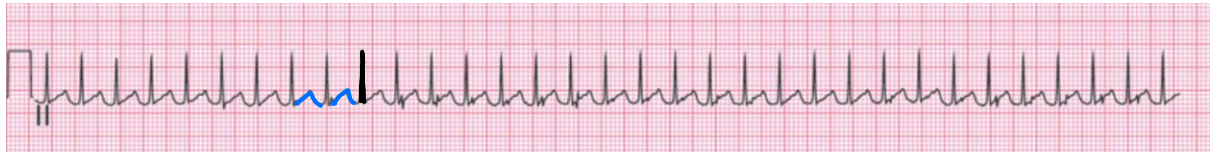25-50 J: DC SHOCK

Rate control: verapamil

Aminophylline ⇒ ↑ Risk of MAT

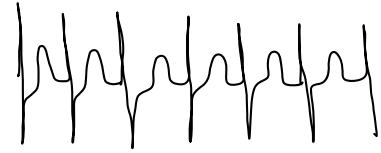


Paroxysmal supraventricular tachycardia



Management of crashing patient or SBP < 90/60 mm Hg.

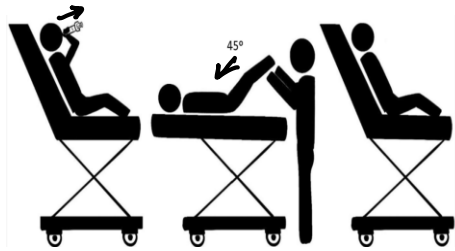↳ Syn. DC SHOCK / cardioversion



Management of patient with SBP > 90/60 mm Hg

* Home management: Etipamil is a short-acting intranasal calcium channel blocker used for paroxysmal supraventricular tachycardia

* Hospital management



1. Vagal ⊕ = carotid sinus massage
face ice pack
modified Valsalva
2. IV Adenosine 6mg → 12mg

↓ fails
Syn. DC SHOCK

* Best management for prevention of PSVT episodes

↓
1°

A. CATHETER ABLATION

B. oral verapamil: (Pill in THE POCKET)

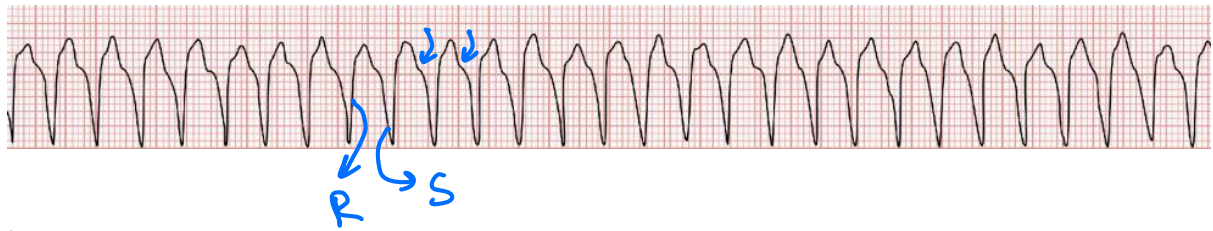
PANIC ATTACKS

- BZD: ?
- SSRI: PAROXETINE

HOLTER device


loop Recorder
↳ 7 days *

Ventricular tachycardia JOSEPHSON SIGN



- 1. - AV dissociation
- 2. - Cannon a waves in JVP
- 3. - Premature ventricular complexes

- Why PVC is bad? EDV ↓ CO ↓



- Fusion beat

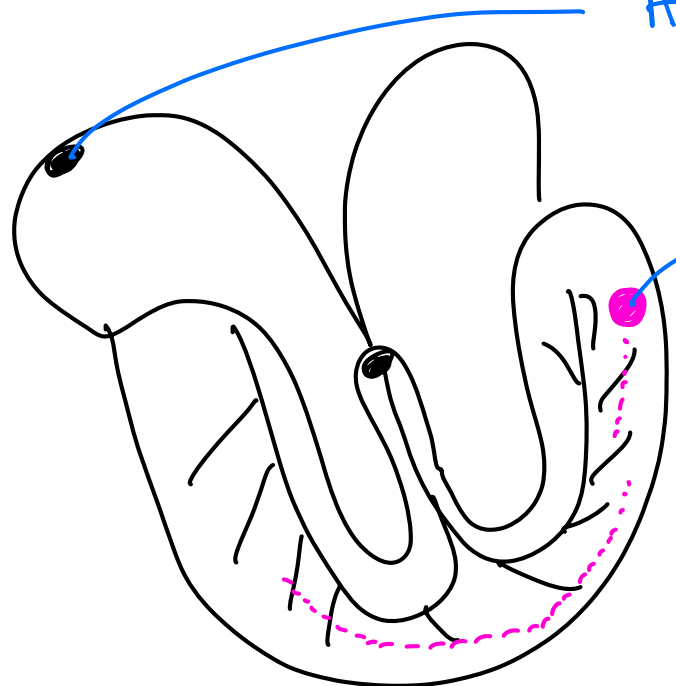
Atrial Rate: 100/min

* AV dissociation

V. Rate: 200/min

intermyocyte conduction
slower than Purkinje
brood RS complexes

PREMATURE VENTRICULAR CONTRACTIONS



early contraction of partially filled ventricle

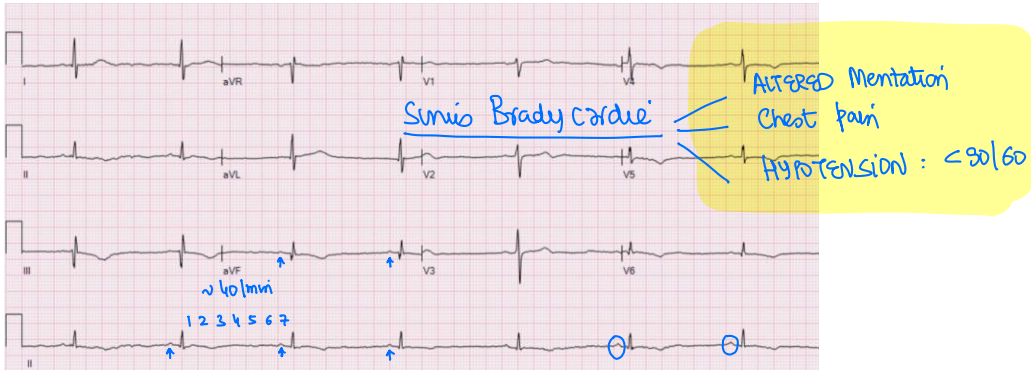
$n = 0.5 \text{ sec: EDV: } 130 \text{ ml}$
 $V.T = 0.1 \text{ sec EDV: } \downarrow \downarrow$

Rx: PVT: defibrillation

ASYMPTOMATIC BRADYCARDIA : T_v ↓



Management of symptomatic bradycardia



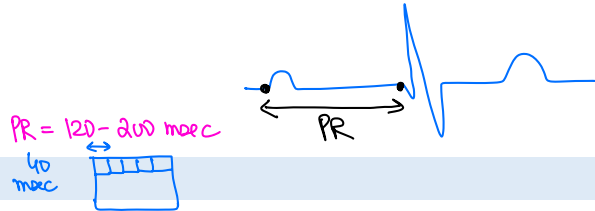
1. IV Atropine 1 mg IV, max dose = 3 mg

2. Other drugs

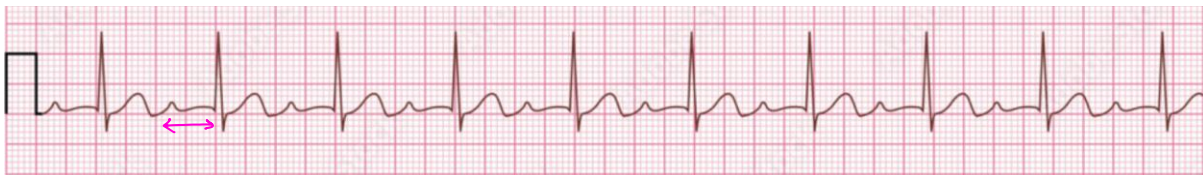- dobutamine
- Epinephrine

3. Temporary pacing

- T.C.P Trans-cutaneous - PACER
- T.V.P Trans-venous




First degree heart block



Causes

1. Physiological MC: MARATHON RUNNER
2. Rheumatic fever
3. Sarcoidosis
4. Hemochromatosis
5. Endo-myocardial fibroelastosis

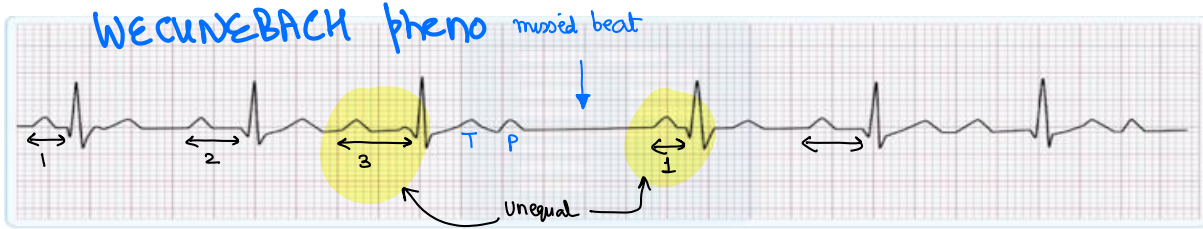


ECG findings

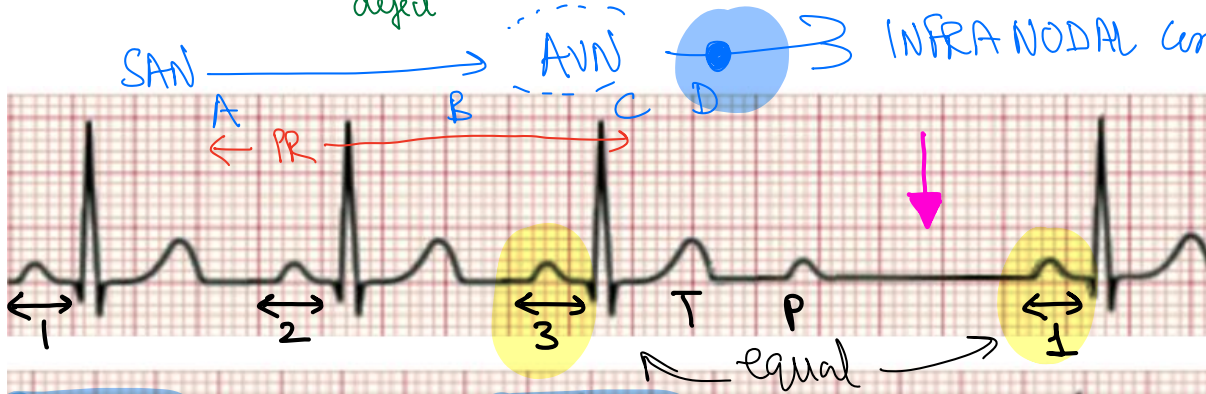
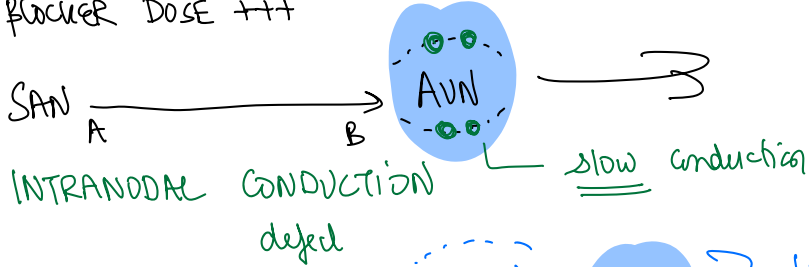
PR > 200 msec

Pacing: Not recommended

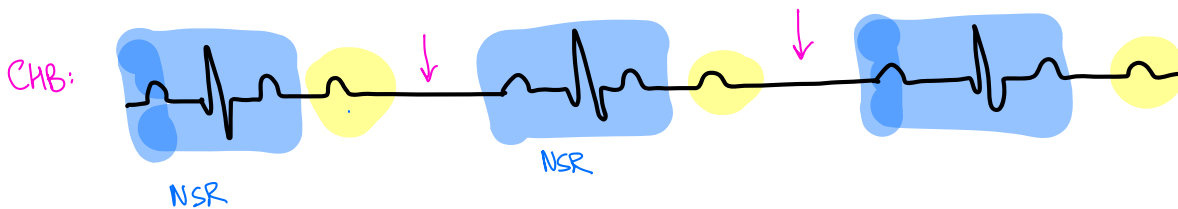

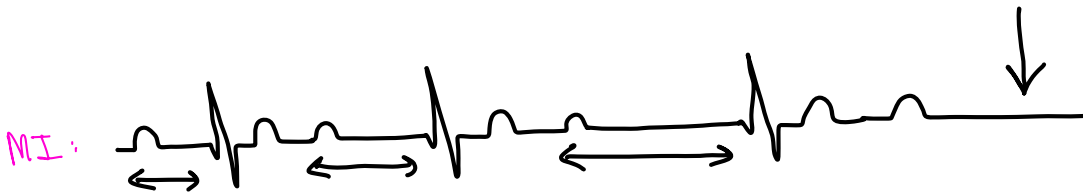
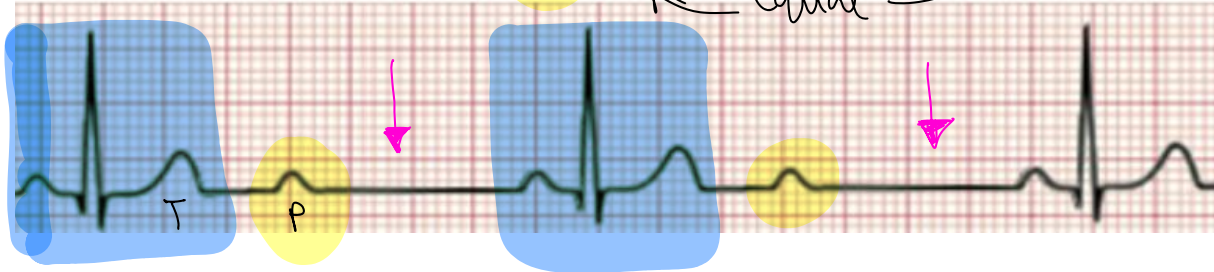
Mobitz I vs Mobitz II heart block



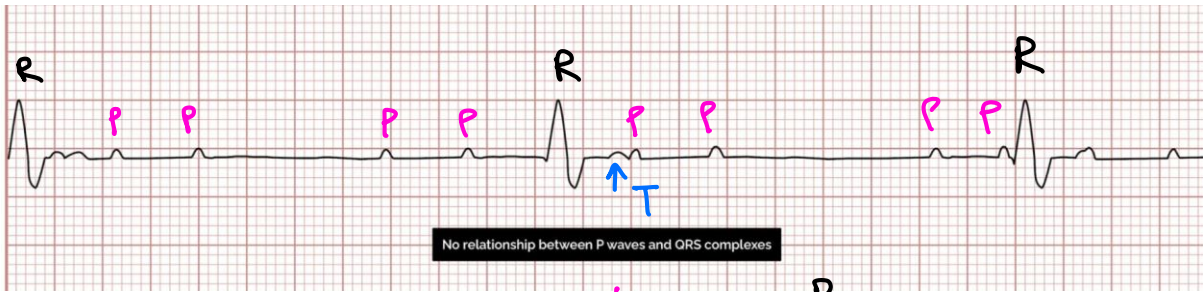
β blocker DOSE +++



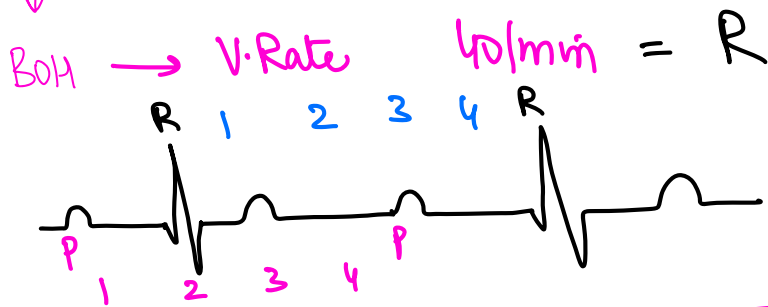
2:1 block



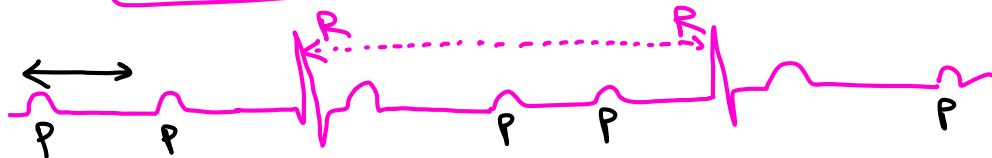
3rd degree heart block | STOKES Adom | Complete H. Block



SAN → A. Rate 100/min = P
 ↓
~~AVN~~ **No** conduction AV dissociation




$R-R = 300/4 = 75/min : V. Rate$
 $P-P = 300/4 = " : A. Rate$



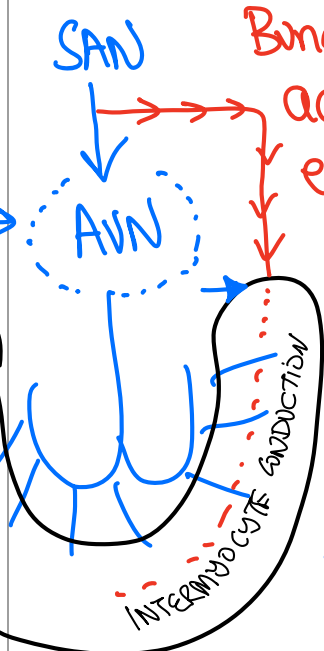
Rx: dual chamber pacing

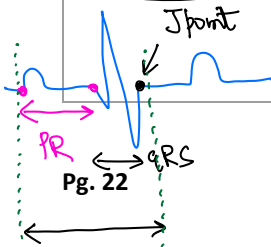
Summary of ECG Special findings

$\updownarrow < 2.5 \text{ mmv}$
 $\leftrightarrow < 120 \text{ msec}$

<p>P Wave *</p>	<p>P- Pulmonale: RAE $\uparrow > 2.5 \text{ mmv}$</p> <p>P- Mitrale: LAE $\leftrightarrow > 120 \text{ msec}$</p> <p>Pseudo-P- Pulmonale \downarrow</p> <p>Absent P Wave \downarrow HYPOKALEMIA</p> <p>COPD: PAH: Rt chamber ++</p> 
<p>Q waves *</p>	<p>Deep Q waves MI</p> <p>S1Q3T3 pattern ← MASSIVE Pulm. embolism</p> <p>deep S: lead I</p> <p>deep Q: lead II</p> <p>T wave inversion: lead III</p> <p>RV strain</p>

- A-Fib^N, holiday heart syn^N
- SSS
- K⁺

<p>Short PR interval</p>	<p>Prolonged PR interval</p>
<p>Tachy: *</p> <p>Radios ablation</p> <p>vagus →</p> <p>PR $\propto 1/HR$</p> <p>Anxiety, Graue's, phaeo^N, HF</p> <p>Wolf Parkinson white syndrome</p> <p>SAN</p> <p>Bundle of KENT</p> <p>accessory pathway</p> <p>early ⊕ of ventricles</p> <p>EDV ↓ Co ↓</p> <p>do palpitations</p> <p>exercise intolerance</p> <p>family H/O SCD +</p> <p>INTERMYOCYTE CONDUCTION</p> <p>J point</p> 	<p>PR interval remains normal in mobitz II heart block</p> <p>1. 1st degree H.B</p> <p>2. 2nd degree HB</p> <p>Mobitz I</p> <p>WENCKEBACH</p> <p>≠ intranodal conduction</p> <p>3. HYPOTHYROIDISM</p>



- A. SHORT P-R
- B: \uparrow delta wave
- C. PJ interval = normal
- PR + QRS


DOC: WPW or LGL \Rightarrow Procainamide or flecainide
 Toc: " " \Rightarrow RFA



qRS Complex abnormalities

Narrow qRS tachycardia

PSVT



Broad qRS tachycardia

VT



Delta waves


WPW

J waves/ Osborn waves

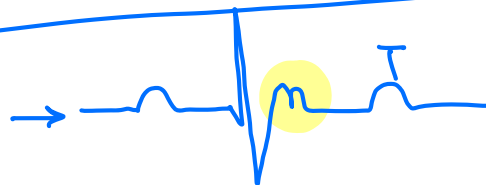
HYPOTHERMIA

Epsilon waves

ARVD




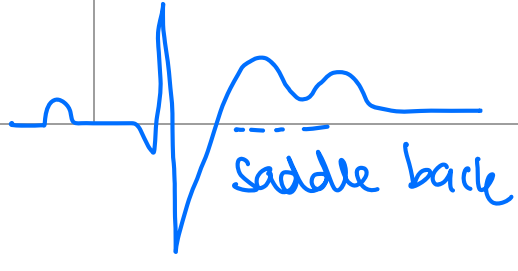
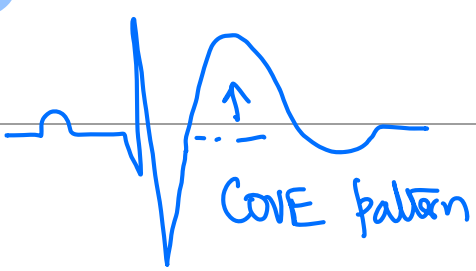
clo Palpitations \rightarrow



Rx: ICD

ARVD: desmosomes #, **Fibrofatty Replacement of RV**
 SCD in sibling

ST elevation	ST depression
<p>E: Electrolytes: K^+ ↑</p> <p>L: LBBB</p> <p>E: Early Repolarization variant</p> <p>VA: Ventricular Aneurysm</p> <p>T: Trauma</p> <p>I: ischemia</p> <p>O: Osborne wave</p> <p>N: Non occlusive vasospasm</p> <p><u>variant</u> Prinzmetal Angina</p> <p>A: Acute pericarditis</p> <p>B: Brugada syn</p>	<p>1. ANGINA chronic stable, unstable Coronary flow: ↓</p> <p>2. NSTEMI </p> <p>3. K^+ ↓</p> <p>4. digoxin</p>



T wave inversion	Tall Tented T waves	Hyperacute T waves
 <p>- NSTEMI - ANGINA - K↓</p> <p>ST ↓</p>	 <p>HYPERKALEMIA</p> <p>↓</p> <p>* Calcium carbonate</p> <p>* <u>Novel K⁺ binders</u></p> <p>PATIRONEER</p> <p>Sod. zirconate</p> <p>S-P-S</p>	 <p>MI</p>

* SCD in S.E. Asian ♂

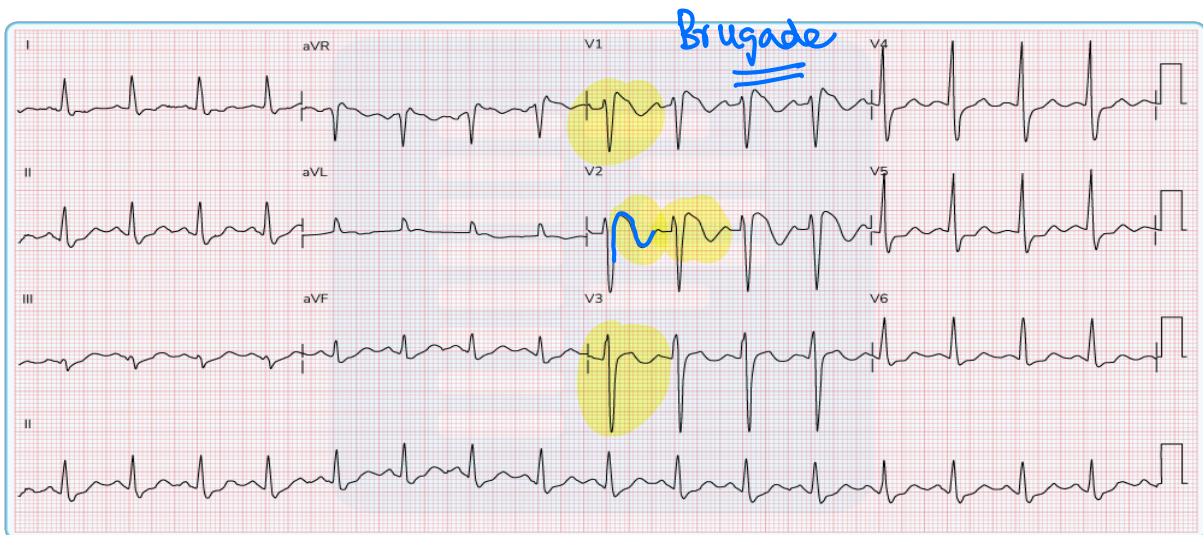


Brugada Syndrome	ARVD
Pathophysiology SCNSA # defective depolarization	Pathophysiology desmosomes #
Agonal breathing and syncope early family H/O (SCD)	Palpitations and recurrent syncope family H/O SCD
ECG ST↑ COVE PATTERN V ₁ -V ₃	ECG epsilon waves
Rx I.C.D	Rx I.C.D

I.C.D = A ARVD

B Brugada

C cardiomyopathy



* MC arrhythmia in HCM/Dcm/Rcm ← HTN, > 65yrs
 ↳ sustained ⇒ A-fib
 grave's

* IVDU ⇒ S. AUREUS



Infective endocarditis

Native valve-IE

- Hospital acquired: Staph AUREUS
- Community acquired: Streptococcus

Prosthetic valve endocarditis

< 2 months: CONS

2-12 months: CONS

> 12 months: → Strep. viridans

TAVR_IE: Transcath. aortic valve Replacement ⇒ ENTEROCOCCI

CIED-IE: CONS


cardiac implantable electronic device



RHD, PACEMAKER, HCM, alcohol, IVDU

FEVER x 2 weeks

DE: Splenic abscess: Splenomegaly



? IE: modified DUKE CRITERIA

Definite IE

1. Pathologic criteria (microorganisms or active endocarditis identified in a vegetation/ intracardiac abscess from cardiac tissue prosthetic material, arterial embolus)
2. Clinical criteria (2 major or 1 major + 3 minor or 5 minor)



Minor Criteria

A. Predisposition: Previous history of IE, injection drug use, prosthetic valve, previous valve repair, congenital heart disease (e.g. bicuspid AV), CIED, more than mild regurgitation or stenosis hypertrophic cardiomyopathy

B. Fever. $T > 38.0^{\circ}\text{C}$ (100.4°F)

C. Vascular phenomenon: arterial emboli, septic pulmonary infarcts, mycotic aneurysm, intracranial hemorrhage, conjunctival hemorrhage, Janeway lesions, cerebral / splenic abscess purulent purpura

D. Immunologic phenomena: Roth spots, positive Rheumatoid factor, Osler nodes, glomerulonephritis

E. Microbiologic evidence: positive blood cultures (not meeting above criteria)

*Erythematous macules
palms, soles* ↑ *S. AUREUS* ↑

ROG - fundus

*Painful
nodules
in
pulp fingers*

Positive culture PCR, or other nucleic acid -based test for an organism consistent with IE from a non - endovascular site or single finding of a skin bacteria by PCR on a valve or wire without additional clinical or microbiological supporting evidence

A. Imaging Criteria: Abnormal metabolic activity on FDG-PET/T within 3 months of implantation of a prosthetic valve, ascending aortic graft, intracardiac device lead

B. Physical exam criteria: New valvular regurgitation on auscultation

MAJOR CRITERIA → MIS

Microbiological Criteria

Bld CULTURE

1. **Positive blood culture:** Microorganisms that occasionally or rarely causes IE isolated from 3 or more separate blood culture sets (Non-Typical)

2. **Positive laboratory tests**

PCR

→ Q FEVER

-Positive polymerase chain reaction (PCR for *Coxiella burnetti*, *Bartonella* spp., or *Tropheryma whippelii* from blood

↳ cat

-Single blood culture growing *C. burnetti* or phase I IgG Ab titer $\geq 1:800$

-Indirect immunofluorescence assays (IFA) for IgM Ab and IgG Ab to *B. Henselae* or *B. Quintana* with IgG Ab titer $\geq 1:800$

IFA: Igm, IgG

Imaging Criteria

1. Echocardiography or cardiac CT showing vegetation, valvular/ leaflet perforation/ aneurysm, abscess, pseudoaneurysm or intracardiac fistula

2. FDG-PET /CT with abnormal metabolic activity involving a native or prosthetic valve, ascending aortic graft, intracardiac device leads or other prosthetic material

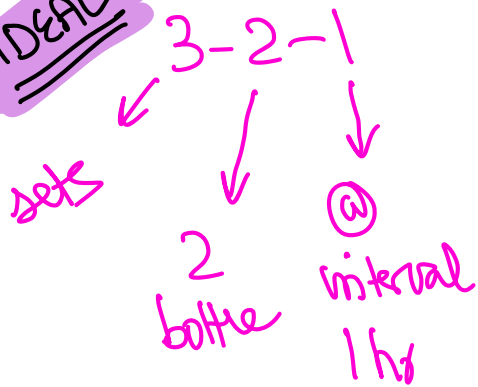
Surgical Criteria: Evidence of IE documented by direct inspection during heart surgery

8Am

9Am

10Am

IDEAL



Update

2 sets of 2 bottles, same Time

Typical organism ↑


* MR AR, MS, AS = Highest incidence of IE

* ASD = least incidence of IE

HTN CRISIS: >180/120 + Target organ



Must know Cardiac emergencies

<p>Acute pulmonary edema due to Hypertensive crisis</p> <p>↓</p> <p>DOC: N.T.G. DRIP</p> <p>LMNOP</p> <ol style="list-style-type: none"> 1. Lasix: Furosemide 2. Morphine: vagotonic 3. NTG 4. O₂: NIV: Bi-PAP 5.  <p><u>Acute heart failure</u> <u>HTN CRISIS</u></p>	<p>Cardiogenic shock</p> <p>AHF + AKI findings</p> <p>WF</p> <p>findings</p> <p>Rx:</p> <p>↓</p> <p>CONSERVE O₂</p> <ol style="list-style-type: none"> 1. Norepinephrine: ↑ coronary flow 2. dobutamine <p>β₁ ⊕</p> <p>α₁ #</p> <p>☹️ dopamine</p>	<p>HFrEF EF < 40%</p> <p>CHF ↑</p>
		<ol style="list-style-type: none"> 1. ARNI Valsartan + Sacubitril or 1. ACEi 2. β blockers Carvedilol, metoprolol bisoprolol 3. M.R.A 4. SALT2i Empagliflozin <p>Natriuresis + SBP ↓</p>

* HFrEF = < 40% : ARNI

* HFpEF = EF > 50% : ARNI

↑

HTN

✓ ARB: → ATII Receptor blockade

AT₁ receptors #

<p>Hypertensive emergency leading to acute pulmonary edema *</p>	<p>Note: beta blockers are contraindicated in Acute HF NTG DRIP *</p>
<p>Hypertensive emergency leading to hemorrhagic stroke * Target BP</p>	<p>Nicardipine > labetalol HTN: face, arm weakness</p>
<p>Hypertensive urgency</p>	<p>> 180/120 mmHg T.O.D Rx: ORAL ACEi</p>
<p>Posterior reversible encephalopathy syndrome</p>	<p>HTN visual blurring: blindness, unconscious MRI: vasogenic CEREBRAL edema: <u>occipital</u> L Rx: Nicardipine parietal</p>
<p>Malignant hypertension FIBRINOID necrosis</p>	<p>Retinopathy ⇒ Retinal hemorrhage papilledema Rx: Nicardipine > SNP</p>
<p>Scleroderma crisis</p>	<p>oral ACEi</p>
<p>Nitroprusside acts within seconds and has onset within 2 minutes. It breaks down to produce NO (acts via cGMP) and Cyanide. Must be given in light protected infusion set. Antidote for toxicity: <u>Sodium thiosulfate</u> (preferred) and <u>Hydroxocobalamin</u> (binds cyanide)</p>	

☹️: amyl nitrate inhalation

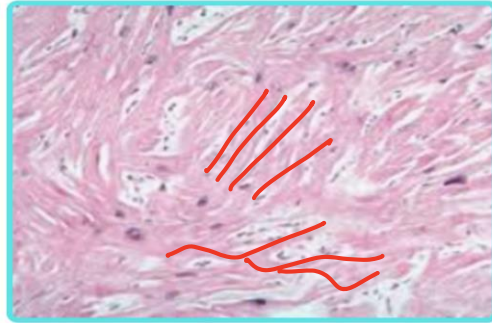
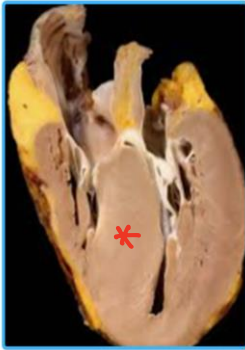Refractory HF

1. CRT cardiac Resynchronization THERAPY
2. CRT-D " " + ICD
3. LVAD LV assist device | HEART-MATE

$$EF = \frac{SV}{EDV} = \frac{80}{130} = 65\%$$

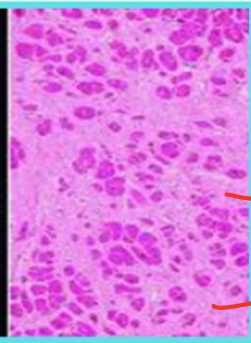
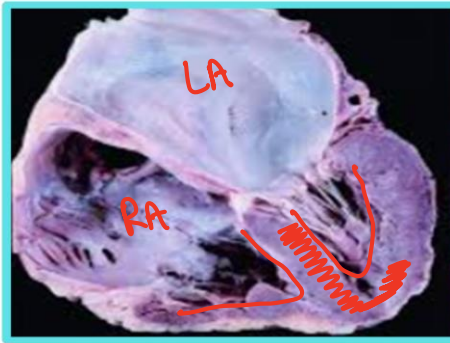
Cardiomyopathy (Histopathology)

HCM



HELPER
SKELETAL
app

RCM

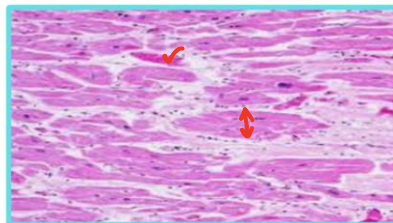
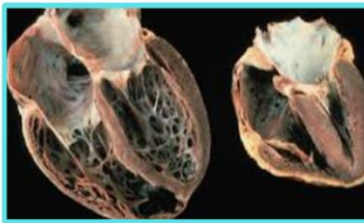


Atrial size > Ventricular size

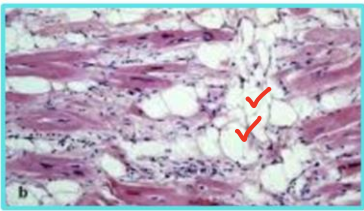
* RARE

AMYLOIDOSIS: M/C

DCM



- global hypokinesia
- HYPERTROPHY of myocyte



ARVD
FIBRO-fatty deposition
of RV

NYHA: gd III
minimal activity
↑ =

* LVF = lungs + = pulm edema: SOB, orthopnea

* RVF = Rest of body ⊕ = Pedal edema
Ascites

JVP ↑ pulsatile

Imv: Pro-NT - BNP ↑

CXR: Bat wing edema +

AHF ⇒ LMNOP

~~HRAT~~ : → β blockers
☹️